

## Therapeutic drug monitoring (AEDs)

During my placement in chemical pathology I identified some of the tests with relevance to my own specialism. One of these is therapeutic drug monitoring of anti-epileptic medications such as Carbamazepine and Phenytoin. (Other antiepileptic drug levels are monitored but not on site). Antiepileptic drugs continue to provide the most effective therapy for epileptic seizures but in clinical practice the desired effects of the drug must be balanced against possible toxicity (Salinsky et al, 2002).

The goal of Anti-epileptic drug (AED) therapeutic drug monitoring (TDM) is to optimise the individualised clinical outcome for patients with epilepsy, by supporting management of medication with measurement of drug concentration in the blood (Patsalos & Berry, 2013). To optimise efficacy while avoiding toxicity is the purpose – toxicity can resemble neurological disease and may even lead to escalations in medication therapy where the dose was already too high (Krasowski, 2011).

Reference ranges may be difficult to establish but can be defined as: A lower limit below which therapeutic effect is unlikely, and an upper limit above which toxicity is likely. (Patsalos et al, 2008). The reference ranges may also depend on how the drug is being used (e.g. for different seizure types, bipolar disorder or chronic pain) (Krasowski, 2011).

'Since many people take more than one drug, there may be interactions between the drugs that affect the way the body absorbs or metabolises one of them. Also, some patients do not take drugs as prescribed or instructed. Monitoring can identify these cases' (Lab tests online, 2011).

Collecting the blood at the correct time is important. This may be immediately prior to administration of the next dose, or at a specified time following dose administration. (Lab tests online, 2011).

It should be remembered however that there are limitations to every test and 'a strict use of the therapeutic range cut-offs to classify patients as sub therapeutic, therapeutic, or toxic will result in considerable numbers of misclassifications' (Warner et al, 1998).

While drug monitoring may be best assessed with blood tests it is important for Clinical Neurophysiologists to recognise the expected changes apparent on the EEG recording with certain drugs. Drug induced EEG changes are usually diffuse and symmetrical across both hemispheres of the brain but in some instances may be focal. There are few drug effects distinguishable by visual assessment of the EEG and they are also often non-specific changes (Pressler et al, 2007).

It is of particular importance to be able to detect signs of toxicity on the EEG as NICE (2012) guidelines CG137 state that regular blood monitoring in adults and children is not recommended as routine, but only if clinically indicated (suspected non-adherence, suspected toxicity, adjustment of phenytoin dose, management of pharmacokinetic interactions, status epilepticus, organ failure or certain situations in pregnancy).

Clinical signs of toxicity may include ataxia, nystagmus, Diplopia, and drowsiness, along with diffuse slowing of the EEG (Shomer & Lopes da Silva, 2011) Carbamazepine is noted for producing slowing of ongoing activity into the theta range on the EEG, even where there is a good therapeutic response and no obvious sedation (Pressler et al, 2007).

Gross intoxication of anti-epileptic drugs may be easily detected on neurological examination and confirmed using lab tests, however more subtle effects of prolonged therapy on brain function, particularly cognitive abilities and behaviour may be more difficult to assess clinically. This is particularly critical in children and young adults where learning is of greater importance (Salinsky et al, 2002).

## The following is a brief example of a case demonstrating the effects of Carbamazepine Toxicity in the EEG

**2009** – (Female patient age 2 years)

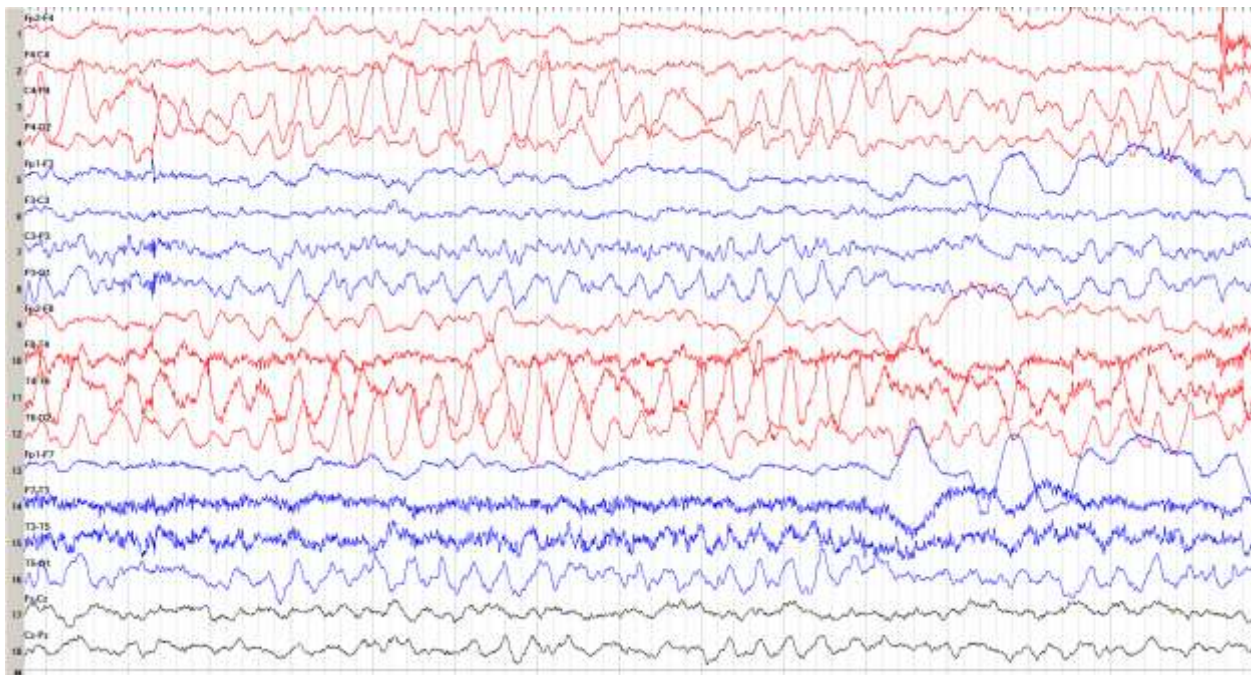
Investigated with EEG due to recent seizures associated with illness. The EEG was within normal limits suggesting a likely diagnosis at this point of febrile convulsions.

**2014** – (Age 7 years)

**July** - Patient admitted to hospital with status epilepticus requiring intubation and ventilation on Intensive Care. The clinical diagnosis was of encephalitis but all investigations were normal.

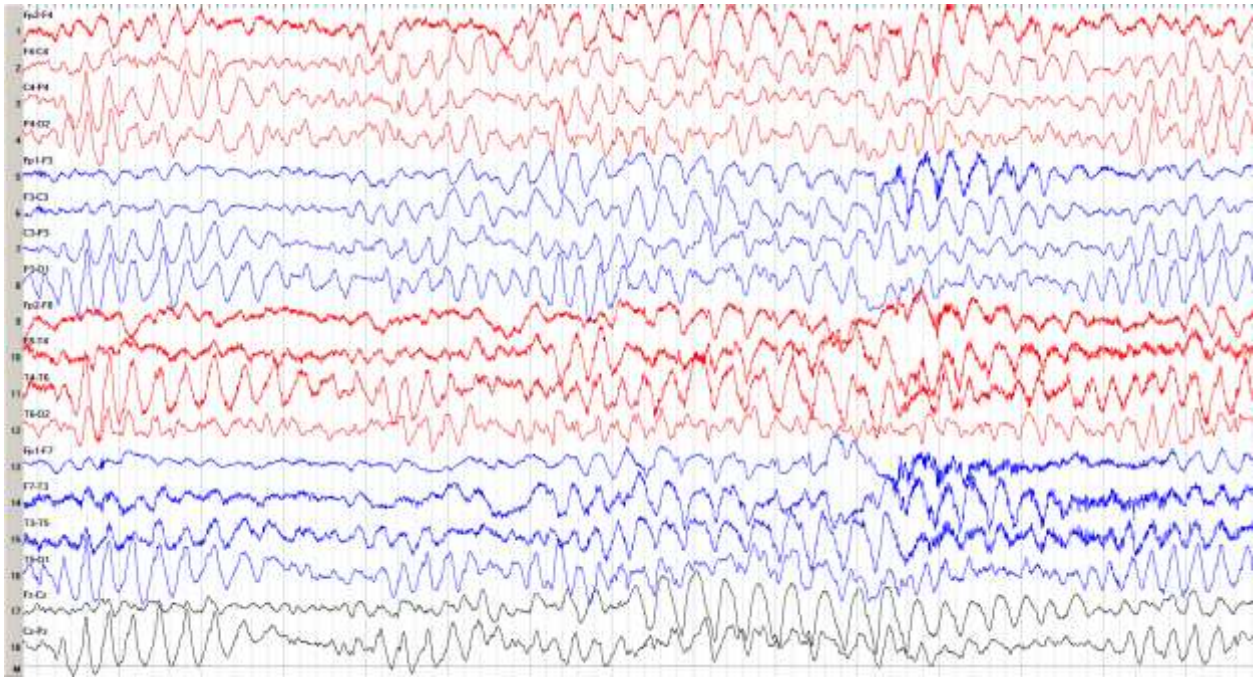
**August** – Admitted to Paediatric inpatients following a further seizure – required IV diazepam to terminate. The patient is not currently taking any regular anticonvulsant medications.

EEG performed – Abnormalities suggestive of a post ictal state or underlying structural abnormality (repeat recommended within a few weeks to determine if changes post ictal only)



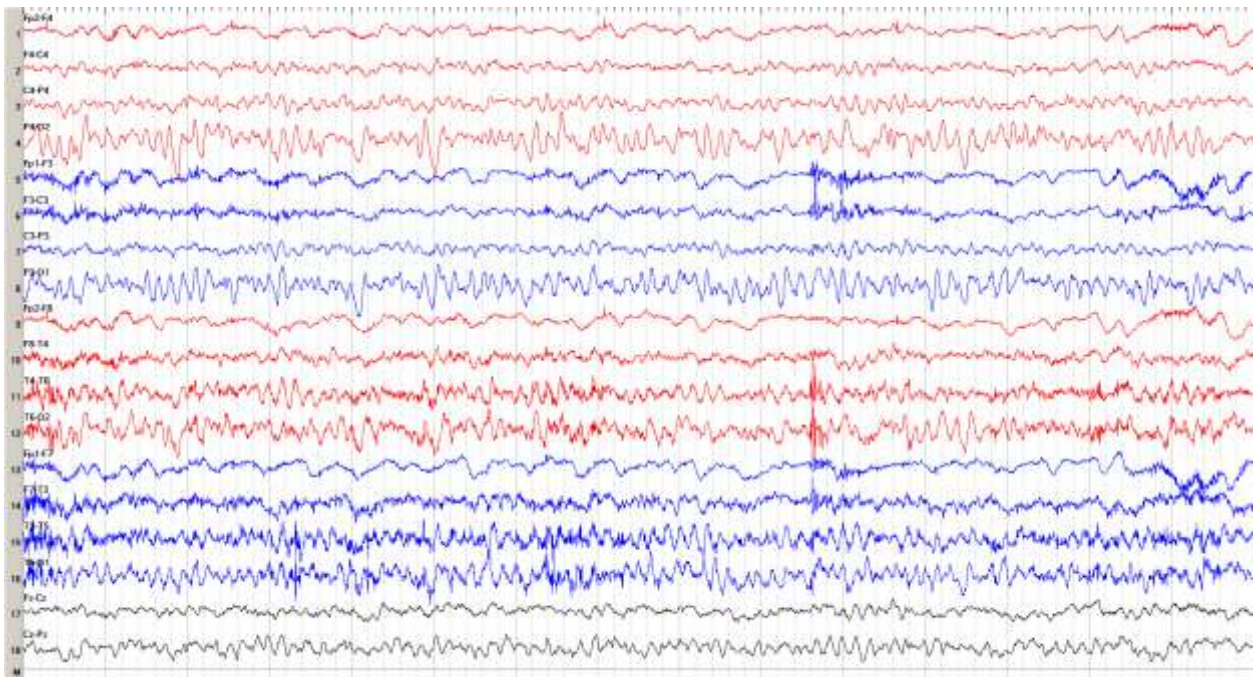
**Above:** sample of EEG showing excess slow activity with emphasis over posterior regions, Right > Left. (right hemisphere shown in red, left hemisphere shown in blue)

**September** – attended for EEG as outpatient. Had since been started on Tegretol 5mg BD. The EEG showed a marked deterioration compared to the previous recording. The changes suggested either a neurodegenerative disorder (such as Angelman's syndrome) or a potential toxicity of Carbamazepine.



**Above:** sample of EEG showing more widespread excess slow activity. The slow activity can no longer be attributed to a post ictal state as in the previous recording as the patient had been seizure free for several weeks. There is also absence of a posterior alpha rhythm which is suggestive of cerebral dysfunction.

**December** – attended for EEG as outpatient. Tegretol stopped and EEG requested to determine if previous abnormalities were related to the Carbamazepine. EEG showed a marked improvement with no abnormalities suggestive of a neurodegenerative disorder.



**Above:** sample of EEG showing a marked improvement. The posterior alpha rhythm has returned and there is little or no excess background slow activity. The record is within normal limits relative to the age of the patient. This improvement following withdrawal of Tegretol suggests there is no neurodegenerative abnormality.

## Summary

In this case there were no apparent clinical symptoms suggestive of Carbamazepine Toxicity. The patient had a recent diagnosis of epilepsy (July 2014) and required urgent treatment to bring seizures under control. The use of the EEG in this case was to differentiate between Carbamazepine toxicity and a potential neurodegenerative disorder as the abnormalities were non-specific and could have been attributed to either. The improvement of the EEG background following withdrawal of Tegretol indicated the cause to be Toxicity. However this is an isolated case and determination of toxicity took several months. Lab tests provide a quantitative and quick assessment of the Carbamazepine levels but they should not be used in isolation.

## References

Krasowski M (2011) 'Therapeutic drug monitoring of antiepileptic medications' available online: <http://cdn.intechopen.com/pdfs-wm/19495.pdf> [accessed on 14/12/14]

Lab tests online (2011) 'Therapeutic drug monitoring' <http://labtestsonline.org.uk/understanding/analytes/thdm/tab/glance/> [accessed on 14/12/14]

NICE (2012) '*The epilepsies: The diagnosis and management of the epilepsies in adults and children in primary and secondary care*' <http://www.nice.org.uk/guidance/cg137/chapter/1-guidance#/pharmacological-treatment> [accessed on 5/1/15]

Patsalos P & Berry D (2013) 'Therapeutic Drug Monitoring of Antiepileptic Drugs by Use of Saliva' available online: <https://www.epilepsysociety.org.uk/sites/default/files/Saliva%20AED%20TDM%202013.pdf> [accessed on 14/12/14]

Patsalos, P, Berry, D, Bourgeois, B, Cloyd, J, Glauser, T, Johannessen, S, Tomson, T, Perucca, E. (2008). 'Antiepileptic drugs - best practice guidelines for therapeutic drug monitoring: a position paper by the subcommission on therapeutic drug Therapeutic Drug Monitoring of Antiepileptic Medications monitoring, ILAE Commission on Therapeutic Strategies'. *Epilepsia*. Vol. 49, No. 7.

Pressler R, Binnie C, Cooper R, Robinson R (2007) '*Neonatal and paediatric Clinical Neurophysiology*' Churchill Livingstone Elsevier, London UK

Salinsky M, Binder L, Oken B, Storzbach D, Aron C, Dodrill C (2002) 'Effects of Gabapentin and Carbamazepine on the EEG and Cognition in Healthy Volunteers' *Epilepsia* 43(5):482-490

Schomer D, Lopes da silva F (2011) '*Niedermeyer's Electroencephalography – Basic principles, clinical applications, and related fields*' 6<sup>th</sup> edition, Lippincott Williams & Wilkins, Philadelphia USA

Warner A, Privitera M, Bates D (1998) 'Standards of laboratory practice: antiepileptic drug monitoring' <http://www.clinchem.org/content/44/5/1085.full#sec-1> [accessed on 5/1/15]